

Classification of Longitudinal Tooth Fractures

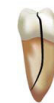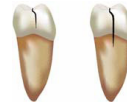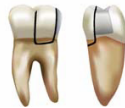Craze Line

Fractured Cusp

Cracked Tooth





Split Tooth

Vertical Root Fracture



	Craze Line	Fractured Cusp	Cracked Tooth	Split Tooth	Vertical Root Fracture
Location	Enamel only Common on marginal ridges	Crown and cervical margin of root	Crown only or crown to root extension (depth varies)	Crown and root; extension to proximal surfaces	Root only
Direction	Occlusogingival	Mesiodistal and faciolingual	Mesiodistal	Mesiodistal	Faciolingual
Origination	Occlusal surface	Occlusal surface	Occlusal surface	Occlusal surface	Root (any level)
Aetiologies	Occlusal forces, thermocycling	Undermined cusp, damaging habits	Damaging habits, weakened tooth structure	Damaging habits, weakened tooth structure	Wedging posts, obturation forces, excessive root-dentin removal
Symptoms	Asymptomatic	Sharp pain with mastication and with cold	Highly variable	Pain with mastication	None to slight
Signs	None	None of significance	Variable	Separable segments, periodontal abscess	Variable
Identification	Direct visualisation, transillumination	Visualize, remove restoration	Biting, remove restoration	Remove restoration	Reflect flap and transilluminate

Classification of Longitudinal Tooth Fractures

	Craze Line	Fractured Cusp	Cracked Tooth	Split Tooth	Vertical Root Fracture
					
Diagnostic Tests	None	Visible fractures of cusps, biting test, transillumination	Transillumination, staining, wedge segments (unseparable), isolated/narrow perio probing, biting test, magnification	Wedge segments (separable)	Reflect flap and transilluminate
Treatment	No treatment needed, aesthetic	Remove cusp and/or restore	Root canal treatment depends on pulpal and periapical diagnosis; restore with full cuspal coverage	Variable, must remove one segment, restore or extract	Remove tooth or fractured root; consider fixed and/or removable bridge, or implant
Prognosis	Very good	Very good	Always questionable to poor	Hopeless (if maintain intact). Variable (if remove segment)	Hopeless for fractured root
Prevention	None needed	Place conservative class II restorations; coronal protection (onlay undermined cusps)	Eliminate damaging habits (ice chewing, etc.); coronal protection (onlay undermined cusps)	Eliminate damaging habits; coronal protection (onlay cusps)	Minimize root dentin removal; avoid wedging posts; reduce condensation forces; use of carbon fiber posts